

## Primary Distal Hypospadias Repair: Tubularized Incised-Plate Urethroplasty (Snodgrass) Versus the Perimeatal-Based Flap (Mathieu)

HESHAM M. EL-SAKET, M.D.

*The Department of Pediatric Surgery, Children's Hospital, Cairo University.*

### ABSTRACT

To determine whether the tubularized incised-plate repair or the perimeatal-based flap technique is more appropriate for the repair of distal hypospadias, a comparative study was conducted and the outcome was evaluated in terms of satisfactory functional and cosmetic results. Between January 2000 and July 2002, eighty patients with distal hypospadias underwent primary repair in a prospective controlled randomized trial. Forty patients were allocated for a Snodgrass procedure; their mean age was 2 years (ranged between 12 months to 4 years). Mathieu repair was carried out for 40 patients; their mean age was 2.5 years (ranged between 14 months to 4 years). The mean follow up period was 12 months (ranged between 8 to 24 months). The mean duration of surgery was significantly shorter for the Snodgrass procedure than for the Mathieu repair (60 minutes versus 100 minutes respectively). The cosmetic and functional results were better in the Snodgrass repair where the meatus was located at the tip of the glans and vertically oriented in all patients. With the Mathieu procedure the meatus was round in shape and horizontally oriented. Three of the patients who underwent Mathieu repair had urethrocutaneous fistulae versus one in the Snodgrass group. The tubularized incised-plate urethroplasty (Snodgrass) technique offers a safe and reliable modality for the primary repair of distal penile hypospadias. Compared to the perimeatal-based flap (Mathieu technique), comparable functional and superior cosmetic results were observed.

### INTRODUCTION

Eighty percent of patients with hypospadias have a meatus in a coronal or subcoronal position [1].

Through the millennia, correction of hypospadias has been the work of dedicated innovators, there have been no easy solutions. A number of surgical procedures and technical modifications for distal hypospadias has been developed and refined through the years to allow for a simple single stage repair that has lessened patients discomfort and decreased complications and cost effectiveness without sacrificing functional and cosmetic results [2].

The perimeatal-based flap (Mathieu) urethroplasty is commonly used for the primary correction of distal hypospadias [3,4]. The most frequent complications after hypospadias repair are urethrocutaneous fistulae and meatal stenosis, which have been reported in up to 21% of patients [5]. Further more; the meatal-based flap repair creates a horizontal and round meatus which is cosmetically less acceptable than a normal slit-like meatus [6,7]. Tubularized incised plate (TIP) repair described by Snodgrass in 1994 provides a technique with a possible low complications rate for correcting distal hypospadias, creating a neourethra of normal diameter irrespective to the plate, glans configuration and location of the meatus [8].

The present study was designated to determine whether the Mathieu or Snodgrass repair is the more appropriate treatment for distal hypospadias assessing operative technique, duration, cosmesis of the meatus and morbidity.

### PATIENTS AND METHODS

The two procedures for correcting distal hypospadias were assessed in a prospective randomized controlled trial conducted between January 2000 and July 2002. Eighty consecutive patients were randomized into 2 equal groups. In group A: Snodgrass procedure was performed. In group B: Mathieu repair was done (Table 1). The selected techniques were rigorously applied by the same surgeon. Patients were then followed once a week for the first month, then every month the first year, then every 3 months in the second year to determine any complications and evaluate the cosmetic results.

*Operative technique (Figs. 1 & 2):*

The penis is degloved with a U-shaped incision extending along the edges of the urethral plate to

healthy skin 2 mm proximal to the meatus. Artificial erection test was induced to assess any deviation; if there was significant chordee it was corrected by dorsal plication [9].

The ventral glans is then infiltrated with 1:100,000 epinephrine and the glans wings were created after making parallel longitudinal incisions to define the urethral plate.

In the Mathieu group, a skin flap was outlined proximal to the meatus long enough to reach the tip of the glans. The flap was raised to the meatus and anastomosed to the distal urethral plate with 6/0 polyglactin subcuticular suture on each side (Fig. 3).

In the Snodgrass group [8], the urethral plate was widened by a midline incision along its entire length from the meatus to the glans tip. The incision is carried deeply through the mucosal and submucosal tissue dividing all transverse webs and exposing the underlying corporal bodies. This maneuver opens the plate to a very good extent making it possible to tubularize it over an 8-10 F silicone catheter. Continuous subcuticular 6/0 polyglactin suture was used to fashion the tube (Fig. 4). Dorsal subcuticular tissue dissected from the preputial and shaft skin was rotated ventrally to cover the neo-urethra in both groups [8,10]. The glanular wings were symmetrically closed over the neourethra with 5/0 polyglactin sutures in two layers. Skin closure is achieved by a variant of Byar's flaps. Simple gauze-dressing is applied and the patients were kept on antibiotics for the duration of the indwelling stent. The dressing is removed on the third day and the patient discharged from the hospital. The stent is left in place for 7 days. The patient is instructed for follow up once every week in the first month, then every month in the first year, then every 3 months in the second year. Meatal calibration is carried out once weekly for 2 months.

## RESULTS

Eighty patients with distal hypospadias underwent primary repair. Forty were allocated for a Snodgrass procedure; their mean age was 2 years (range between 12 months to 4 years). Mathieu repair was carried out for 40 patients; their mean age was 2.5 years (range between 14 months to 4 years). The mean follow-up period in both groups was 12 months (range between 8 months to 24 months).

The mean operative duration (defined to be from

placing the traction suture to applying the surgical dressing) was significantly less for the Snodgrass technique than for the Mathieu repair: 60 and 100 min respectively ( $p < 0.05$ ). There were six complications after the Mathieu procedure; four developed a coronal urethrocutaneous fistula, one meatal stenosis and one glanular dehiscence one week after surgery caused by skin break down. Six months later, three fistulae were repaired and the fourth closed spontaneously. The child with meatal stenosis responded to regular dilatations while the patient with glanular dehiscence underwent a successful Snodgrass repair.

In the Snodgrass group, there was one coronal urethrocutaneous fistula, which was closed operatively seven months later. Mild meatal stenosis occurred in two patients and improved by regular urethral dilatation. A mild degree of penile torsion occurred in one case (Table 2).

The resultant meatus was centrally located, vertical and slit-like in all patients after the Snodgrass repair (Fig. 5) whereas most patients in the Mathieu group had a meatus that was distorted, round and horizontal (Fig. 6).

Table (1): Site of the meatus in the different groups.

Site of meatus	Group A	Group B
	Snodgrass procedure	Mathieu Procedure
Coronal	5	6
Subcoronal	20	18
Anterior penile	15	16
Total	40	40

Table (2): Comparison between the two techniques.

	Group A		Group B	
	One suture line		Two suture line	
Operative technique				
Operative duration	Coronal	50 min	Coronal	90
	Subcoronal	60 min	Subcoronal	100
	Anterior penile	70 min	Anterior penile	110
	Mean	60 min	Mean	100 min
Complications	Fistula	1 case	4 cases	
	Meatal stenosis	2 cases	1 case	
	Penile torsion	1 case	–	
	Glanular dehiscence	–	1 case	
Meatus site	Ventrally located		Distorted	
Meatus shape	Vertical Slit-like		Horizontal Rounded	

Table (3): The reported overall complication rates for the Mathieu and Snodgrass repairs for distal hypospadias.

Reference	No. of patients	Overall rates %
<i>Snodgrass:</i>		
Snodgrass 1994 [8]	16	0
Snodgrass 1996 [21]	148	7
Sugarman 1999 [22]	32	6.2
The present study	40	10%
<i>Mathieu:</i>		
Rickwood 1991 [13]	34	15
Uygur 1998 [5]	42	21.0
Buson 1994 [18]	37	18.97
Sariyuce 1997 [19]	52	5.8
Ghali 1996 [20]	216	15.0
The present study	40	15%

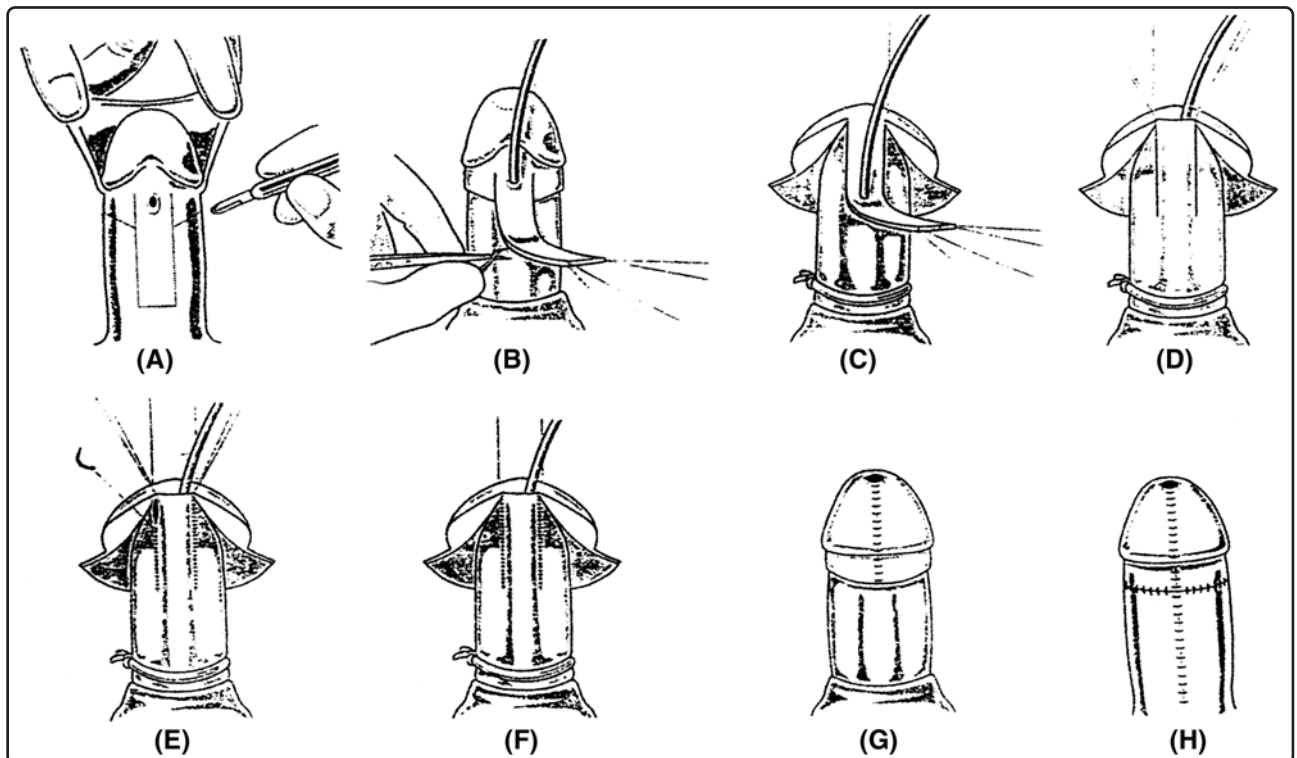


Fig. (1): Mathieu repair: A Ventral meatal-based skin flap is ready for incision. B: Meatal-based skin flap is elevated from the ventral surface of shaft. C: Parallel balanic incisions are made. D: The meatal-based flap is flipped distally. E: Urethroplasty is performed with continuous subcuticular 6-0 vicryl. F: Urethroplasty completed. G: Lateral glans flaps reapproximated with interrupted sutures of 6-0 vicryl. H: Redundant dorsal hood divided in midline and rotated ventrally and trimmed appropriately for skin coverage (Rabinowitz 1999) [7].

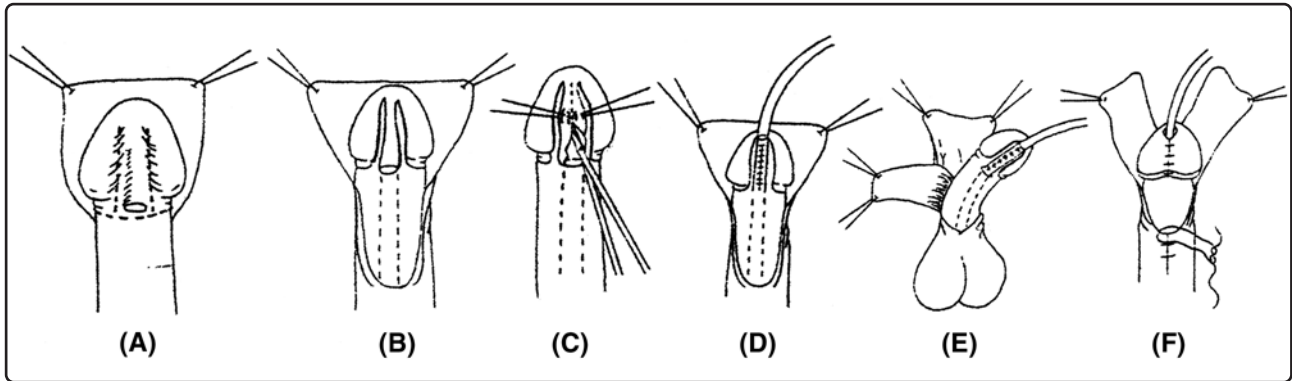
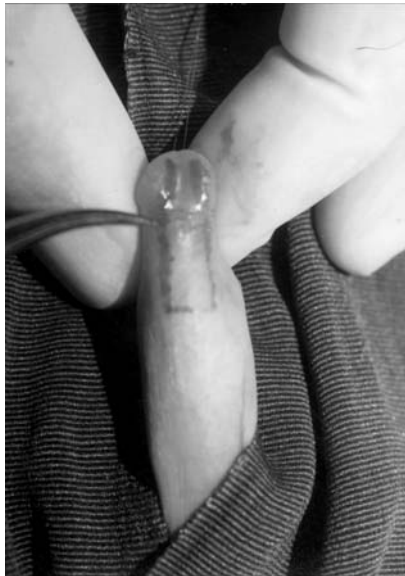
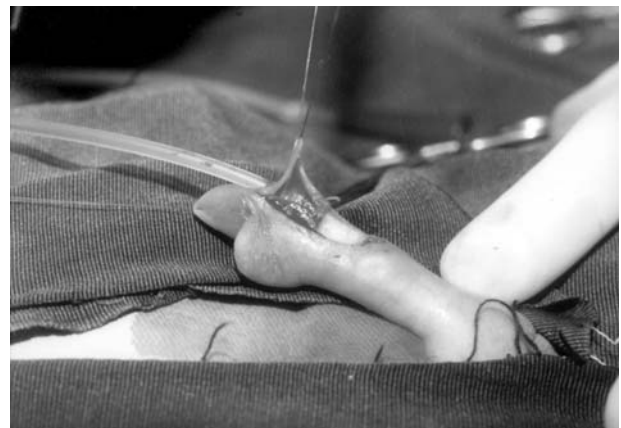
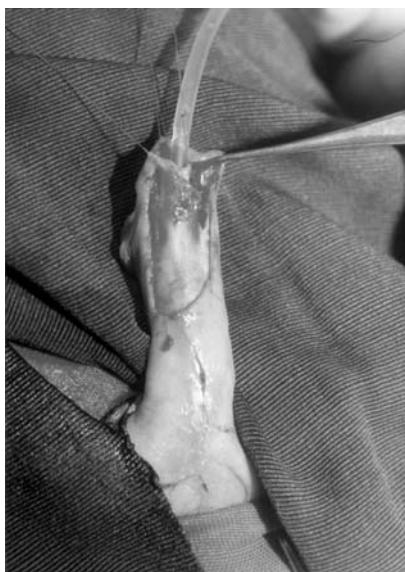Fig. (2): TIP urethroplasty. A: Horizontal dotted line indicates the circumscising incision to deglove the penis. Vertical dotted lines indicate lateral borders of the urethral plate. B: Urethral plate separated from the glans by parallel longitudinal incisions. C: Midline incision of the urethral plate from the meatus to the glanular tip. D: Urethral plate tubularized over a catheter. E: Dorsal subcutaneous tissue mobilized to cover the neourethra. F: Glandular wings; mucosal cells and ventral shaft skin closed (Snodgrass 1994) [8].



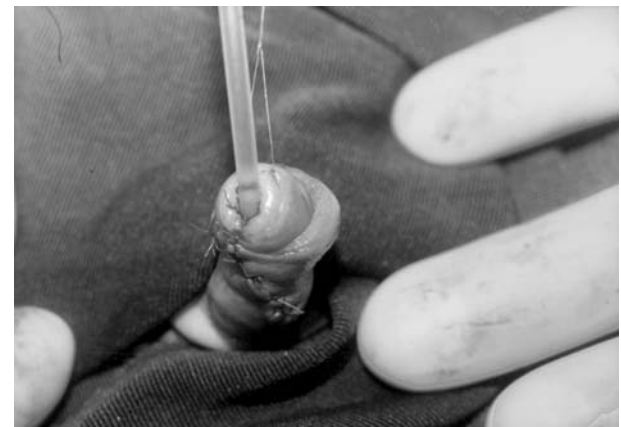A- The ventral meatal-based skin flap is outlined.



B- Meatal-based skin flap is elevated from the ventral surface of shaft.



C- Urethroplasty is performed with continuous subcuticular 6-0 vicryl.



D- Lateral glans flaps reapproximated in midline with interrupted sutures of 5-0 vicryl.

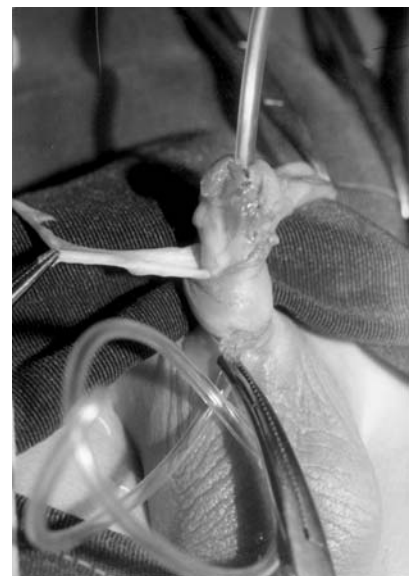Fig. (3): Mathieu repair.

Fig. (4): Snodgrass repair.

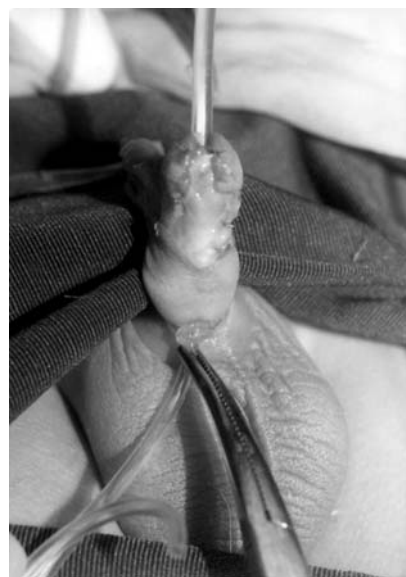
A- Lateral borders of the urethral plate is outlined. Site of midline incision of the urethral plate from the meatus to the glanular tip.



B- Urethral plate tubularized over a catheter.



C- Dorsal subcutaneous tissue mobilized to cover the neourethra.



D- Glanular wings; mucosal collar and ventral shaft skin closed.

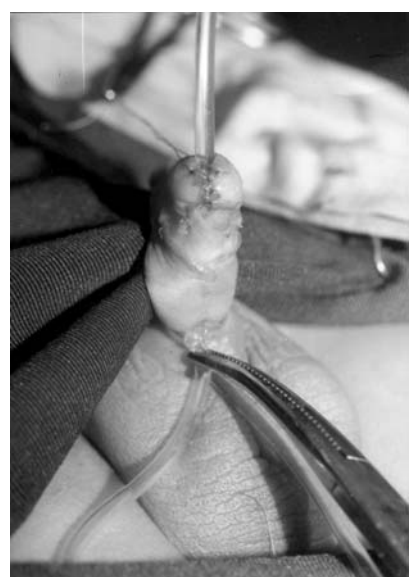

Fig. (5): Snodgrass: Meatus is centrally located, vertical and slit-like.

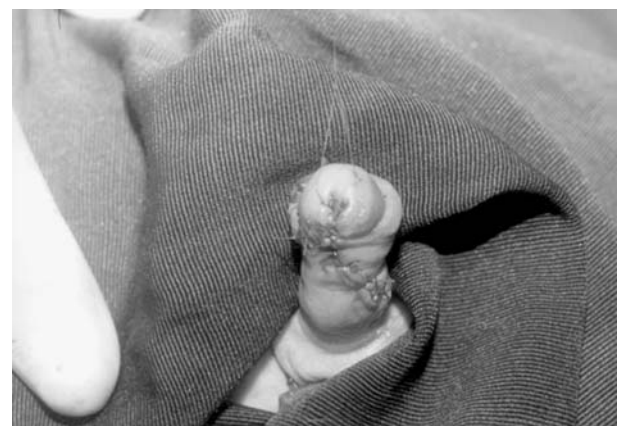
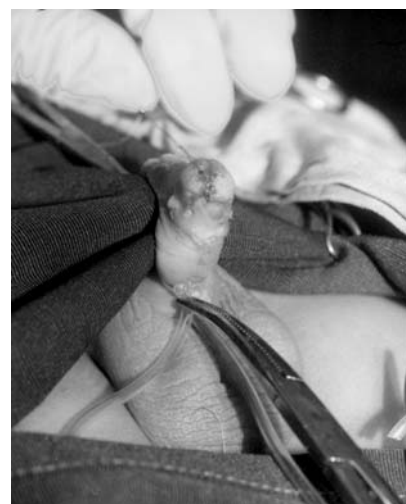
Fig. (6): Mathieu: Meatus is centrally located, horizontal and rounded.

## DISCUSSION

The majority of boys with hypospadias have a distal meatus with minimal chordee [1]. There are various surgical procedures to correct such defects. The choice of operation for repair of distal hypospadias is determined by a number of factors including the configuration of the glans and meatus and associated degree of penile curvature [12]. Another important consideration in hypospadias surgery is the final cosmetic result. The ultimate goal is a penis that is not only functionally normal but cosmetically as well.

Complications are common after hypospadias repair, ranging from fistula to complete loss of the neo-urethra requiring total reconstruction [13]. The meatal-based flap urethroplasty is commonly used for the primary correction of distal hypospadias. It is used for a noncompliant meatus associated with a flat glans [11]. The incidence of complications (defined as those requiring re-operation) after primary meatal-based flap urethroplasty is reported to range between 5 and 21% for distal hypospadias repair (Table 3). The two-suture lines necessary for the flap increase the risk of developing a coronal urethrocutaneous fistula. There is also an increased risk of meatal stenosis because the blood flow in the distal part of the flap is reduced [14]. The meatal-based flap extending near the scrotal junction could result in hair growth at the meatus during puberty. Finally the resultant meatus is horizontally oriented and rounded, although functionally accepted, but it is less cosmetically desirable than the normal vertically oriented, slit-like meatus. Because hypospadias surgery is complex, it is difficult to compare complication rates; especially in distal hypospadias where complication rates are relatively low in recent operative techniques. The surgeon needs to stabilize the many variables present e.g. anatomical variations, tissue handling, suture material, stenting and the surgeon. Hinging the urethral plate was developed as a modification of hypospadias reconstruction to improve the cosmetic appearance of the neomeatus for repairs that preserve the plate [15]. Decision making is simplified by T.I.P urethroplasty. The designation of the meatus as compliant or so called variant does not affect the surgical technique. To address the concern of inadequate urethral plate width, Snodgrass introduced the concept of longitudinal incision of the urethral plate which enables tubularization creating a neo-urethra of normal diameter irrespective of the plate, the glans configuration (grooved or flat) or the location of the meatus [10].

Hinging the urethral plate facilitates glans folding during glanuplasty, extends the meatus to the tip of the penis, provides generous mobilization of the urethral plate for tubularization with or without additional skin flaps and helps to create a cosmetically normal centrally located, vertically oriented urethral meatus [8].

This deep incision does not compromise its viability and the dorsal surface re-epithelialized rapidly during the brief period of urinary diversion. With this technique only one suture line is necessary, saving operating time and decreasing the possible risk of a urethrocutaneous fistulae. Also to minimize the risk of fistula formation the urethroplasty should then be covered with a vascularized de-epithelialized transverse island flap of subcutaneous tissue.

Post operative follow up of patients revealed urethral stenosis in 4 patients that improved over a period of 2-3 months using periodic neourethral dilatation. Snodgrass [16] evaluated 72 patients operated upon using T.I.P and reported that the dorsal relaxing incision of the tubularized incised urethral plate did not result in neourethral strictures. Other recent studies indicated that the Snodgrass procedure causes fewer complications than the Mathieu repair (Table 3). Our early reported experience of fistulae formations compares favorably with that of other studies (25% in Snodgrass repair and 75% in Mathieu repair).

The Snodgrass repair was significantly faster than the Mathieu procedure and the cosmetic appearance of the neomeatus is more natural. Prior circumcision or a failed hypospadias repair usually leaves insufficient skin to construct flaps. TIP urethroplasty may be indicated in these situations because it does not require skin flaps and the urethral plate often remains healthy despite prior surgery. Thus the tip urethroplasty is a versatile procedure offering excellent cosmetic results and a low complication rate.

It is recommended that the tubularized incised-plate technique is to be used as the primary repair for children with distal hypospadias in properly selected patients.

## REFERENCES

- 1- Devine C.J.Jr., Allen T.D., Duckett J.W. and Horton C.E.: Hypospadias. *Dial. Ped. Urol.*, 1: 2-4, 1978.
- 2- Mitchell M.E. and Kulb T.B.: Hypospadias repair without a bladder drainage catheter. *J. Urol.*, 135: 321, 1986.
- 3- Dewan P.A., Dinneen M.D. and Ransley P.G.: Hypospadias:

- Duckett pedicle tube urethroplasty. *Eur. Urol.*, 20: 39-42, 1991.
- 4- Gonzales E.T.Jr. and Delaune J.: The management of distal hypospadias with meatal-based vascularized flaps. *J. Urol.*, 129: 119-2, 1986.
  - 5- Uygun M.C. and Erol D.: Lessons from 197 Mathieu hypospadias repairs performed at a single institution. *Ped. Surg. Int.*, 14: 192-4, 1998.
  - 6- Rabinowitz R.: Outpatient catheterless modified Mathieu hypospadias repair. *J. Urol.*, 138: 1074-6, 1987.
  - 7- Ronald R., William C. and Hulgert J.R.: Meatal-based flap Mathieu procedure, *Reconstructive and Plastic Surgery of the external genitalia*, 1999.
  - 8- Snodgrass W.: Tubularized, incised plate urethroplasty for distal hypospadias. *J. Urol.*, 151: 464-5, 1994.
  - 9- Baskin L.S. and Duckett J.W.: Dorsal tunica albuginea plication for hypospadias curvature. *J. Urol.*, 151: 464-5, 1994.
  - 10- Retik A.B. and Borer J.G.: Primary and reoperative hypospadias repair with the Snodgrass technique. *World J. Urol.*, 16 (3): 186-91, 1998.
  - 11- Elder J.S., Duckett J.W. and Snyder H.M.: Only island flap in the repair of mid and distal penile hypospadias without chordee. *J. Urol.*, 138: 376, 1987.
  - 12- Devine C.J. and Horton C.E.: A one stage hypospadias repair. *J. Urol.*, 85: 166, 1961.
  - 13- Rickwood A.M. and Anderson P.A.: One-stage hypospadias repair, experience of 367 cases. *Br. J. Urol.*, 67: 424-8, 1991.
  - 14- Nonomura K. and Asano Y.: Measurement of blood flow in paramental fore skin flap for urethroplasty in hypospadias repair. *Eur. Urol.*, 21: 155-9, 1992.
  - 15- Rich M.A., Keating M.A. and Duckett J.W.: Hinging the urethral plate in hypospadias meatoplasty. *J. Urol.*, 142: 1551-1553, 1989.
  - 16- Snodgrass W.: Does tubularized incised plate hypospadias repair create neourethral stricture? *J. Urol.*, 162: 1159-61, 1999.
  - 17- Van Horn A.C. and Kass E.J.: Glanoplasty and in situ tubularization of the urethral plate; a simple reliable technique for the majority of boys with hypospadias. *J. Urol.*, 154: 1505-1507, 1995.
  - 18- Buson H., Smiley D. and Smiley D.: Distal hypospadias repair without stents: is it better? *J. Urol.*, 151: 1059-60, 1994.
  - 19- Sariyuce O., Roth D.R. and Gonzales E.T.: Distal hypospadias repair with meatal-based flaps on an outpatient basis. *Int. Urol. Nephrol.*, 29: 241-4, 1997.
  - 20- Ghali A.M.A.: Hypospadias repair by skin flaps: a comparison of onlay preputial flaps with either Mathieu's meatal based or Duckett's tubularized preputial flaps. *Byu. Intr.*, 83: 1032-8, 1999.
  - 21- Snodgrass W., Koyle M., Manzoni G. and Caldamone A.: Tubularized incised plate hypospadias repair: results of a multicenter experience. *J. Urol.*, 156: 839-41, 1996.
  - 22- Sugarman I.D., Trevett J. and Malone P.S.: Tubularization of the incised urethral plate (Snodgrass procedure) for primary hypospadias surgery. *BJU Int.*, 83: 88-90, 1999.